

# *The Use of CurX on Keratosis Pilaris*

*E. Koprince, MA*

## **Abstract**

*Objectives.* To demonstrate the efficacy of CurX Anti-Microbial Gel as a treatment for keratosis pilaris in a case study. *Materials and Methods.* Patient with keratosis pilaris applied CurX twice daily for 3 months. She was assessed at baseline and after 4, 8, and 12 weeks of treatment.

*Conclusion.* The case demonstrated that CurX Antimicrobial Gel is beneficial to treat keratosis pilaris resolution of lesions.

## **1. Introduction**

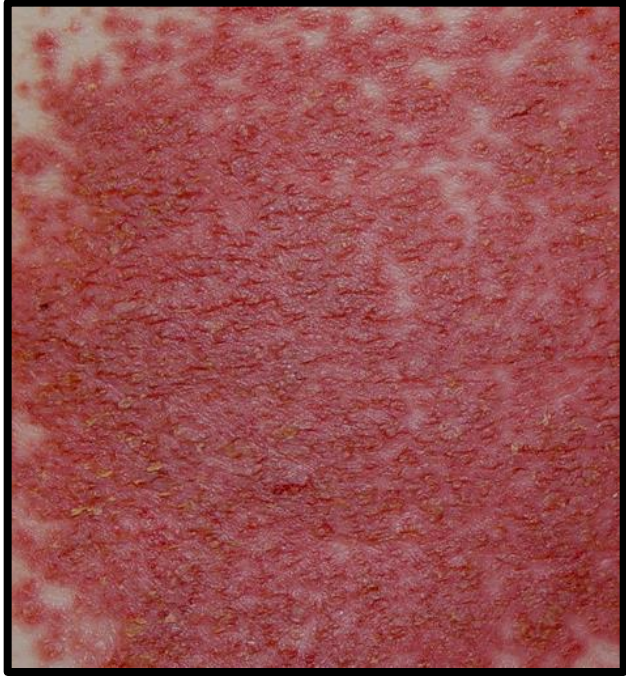
Keratosis pilaris is a common autosomal dominant skin disorder that presents in a symmetrical pattern of erythematous papules on a hyperpigmented base. It typically affects the extremities favoring arms, legs, face, and buttocks and begins in the first or second decade of life. Though it is a benign condition, treatment is aimed at alleviating the patient's cosmetic concerns. Current treatment standards including keratolytic agents and emollients have demonstrated a lack of efficacy. In this case study, I evaluated the clinical outcome of a patient with keratosis pilaris after treatment with CurX Antimicrobial Gel.

## **2. Case Study**

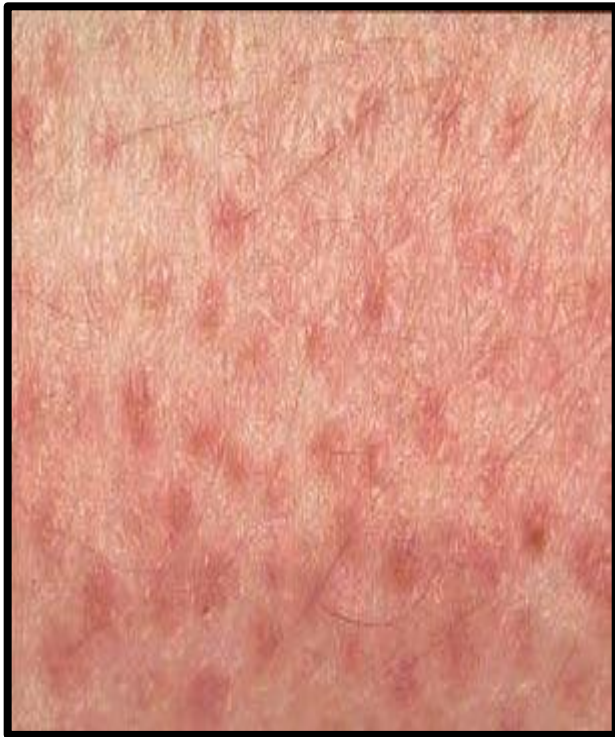A 23-year-old female presents to clinic with Keratosis pilaris. She reports that she has been plagued by the disorder since early childhood and is growing increasingly self-conscious about it. She currently has a dense collection of papules forming a plaque on her lateral right lower leg. She reports that the lesion is not painful but feels that it is disfiguring. She reports that she feels inclined to always wear clothing that covers the region and it has affected her interpersonal relationships as she is reluctant to be intimate with her partner due to the unsightly lesion. She has tried a variety of treatments in the past but found them inadequate. Currently, this lesion is her worst to date and it has been unresponsive to lactic acid treatment. The patient has come in seeking any possible new treatments. I had seen CurX successfully reduce hyperpigmentation and suggested to her that this would be a novel trial for this skin condition and she wished to proceed.

## **3. Result**

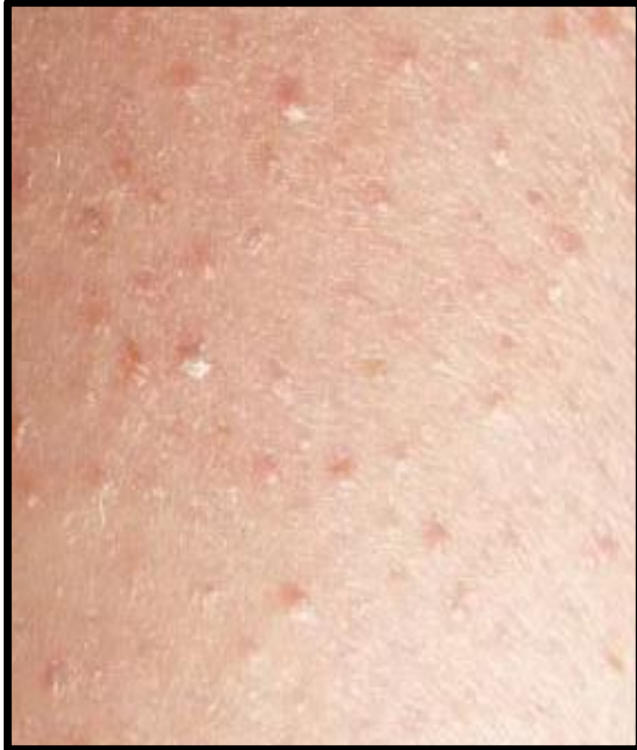A thin layer of CurX was applied to the lesion and surrounding tissues. It was dressed with gauze and kerlix with dressing changes twice daily. The most dramatic reduction of symptoms took place in the first 4 weeks where an estimated 60% of the dense papules resolved. Week 4 revealed a reduction from papules to macules and a significant decrease in the density of the lesion. By week 8 desquamation was apparent as the skin was attempting to heal itself. Week 12 revealed total resolution of associated symptoms.



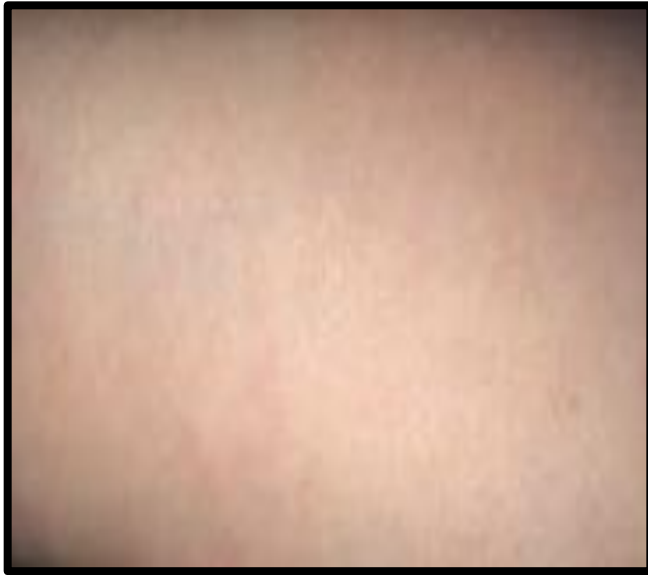**Week 1: Dense  
papules forming a  
plaque**



**Week 4: Reduction  
in density and  
resolution of  
papules to macules**



**Week 8:  
Desquamation  
phase**



**Week 12:  
Resolution**

#### **4. Discussion**

Studies estimate that Keratosis pilaris affects approximately 40% of the population. It often appears in childhood and enters remission by adulthood however for many patients it is a lifelong battle. While this disorder itself is not debilitating, the psychosocial aspect associated with perceived disfigurement can be traumatic for patients. For the patient in this study, anxiety, depression, and sexual self expression were all mitigating factors for seeking treatment.

While the literature is limited considering the pervasiveness of this issue, it is theorized that keratosis pilaris is caused by a dysfunction within the stratum corneum layer of skin. Excessive skin dryness tends to exacerbate symptoms, suggesting that there is an increase in stratum corneum cohesion which results in an excessive loss of moisture. With CurX, this is not a factor as the petrol based formulation keeps the skin hydrated and adjusts the pH to prevent irritation. The hydrophobic properties create a barrier to excessive moisture loss and support a reduction of corneocyte adhesion. This promotes desquamation of the diseased cells and stabilizes retention hyperkeratosis. CurX is effective because it supports the healthy lipid structure and configuration of the stratum corneum, which endows this layer with its superior barrier properties.

## **5. Conclusion**

CurX Antimicrobial Gel is an effective treatment for keratosis pilaris and a comparative study of CurX versus karyolytic agents evaluating for transepidermal water loss is recommended. With the effectiveness of treatment demonstrated in this case study, I believe CurX to be a more efficient treatment for this troubling skin disorder.